

BOFAS Evidence Based Commissioning guidelines Acquired Adult Flatfoot Deformity

1. Introduction

- A flatfoot deformity is a foot with a low or flat medial longitudinal arch. This is usually associated with deformity of the hindfoot in the form of a valgus heel and can be associated with midfoot problems such as arthritis or forefoot deformities such as bunions. A tight gastrocnemius is a common finding.
- Flatfeet are a normal physiological variant affecting 20-30% of the population. However, the majority of these will have no symptoms and will not be affected in work or recreational activity and do not require treatment.
- This Guidance Document pertains to those patients who have pre-existing flatfeet that are symptomatic and those with previously normal feet that develop symptomatic flatfeet.
- A symptomatic Flatfoot deformity in an adult is the final common pathway for a number of local and generalised conditions (See Appendix 1). Most commonly this is due to Acquired Adult Flatfoot Deformity (AAFD) due to Posterior Tibialis Tendon Dysfunction (PTTD).
- These terms are often used interchangeably though AAFD is a more general term that can include a number of aetiologies but usually refers to decompensation of a pre-existing flatfoot that becomes more painful and progressively flattens. PTTD is a more specific term referring to feet in which the main pathology is dysfunction of the Tibialis Posterior tendon. The key is that in both of these conditions

there will be a deteriorating foot shape.

- This Commissioning Guideline document focuses on AAFD due to decompensation of pre-existing flatfeet and PTTD. However, these conditions cannot be considered in isolation and attention must be paid at all stages of the flatfoot pathway to the possibility of alternative diagnoses, particularly those requiring urgent treatment such as the Charcot foot (the specific pathway for this is in the Diabetic Foot Commissioning Guideline).
- The commonest symptoms are increasing medial ankle and arch pain on activity. In severe deformity lateral pain due to fibula impingement can be seen. Occasionally this may be the only site of pain.
- Symptoms may also be present to due to common associated conditions such as plantar fasciitis, hallux valgus and hallux rigidus,
- As the condition progresses painful arthritis may develop with increasing stiffness and rest and night pain. Mobility becomes significantly affected and the foot shape is not correctable.
- The prevalence of AAFD in the UK is approximately 6%. The primary risk factors are a pre-existing flatfoot, female gender, age and weight. A random sample of females over the age of 40 in one UK GP practice found a prevalence of 3.3%, all previously undiagnosed (Kohls-Gatzoulis, Woods, Angel, & Singh, 2009)
- Other risk factors for AAFD include gastrocnemius contracture, ligamentous laxity, trauma and diabetes.
- The treatment of AAFD includes non-operative and operative interventions. Accepted non-operative interventions

include: activity modification, orthotics and footwear adjustments, bracing/splints, immobilisation in a walker boot or cast, physiotherapy and appropriate analgesia.

- Image guided/targeted injections may be used for symptomatic subfibular impingement or hind/ midfoot degeneration. However they should not be used on the medial side for the tendon itself as this is a major risk for acute rupture.
- The surgical approach is determined by staging of the disease severity most commonly using the Strom and Johnson Classification (Appendix 2) and assessment of the pathoanatomy determines.
- The basic surgical approach those feet without degeneration is a reconstruction of the failed tendon with a tendon transfer, a calcaneal osteotomy and spring ligament reefing. This is often supplemented with other procedures, for instance gastrocnemius release, subtalar arthrodesis or isolated joint fusions.
- In those feet with joint degeneration a triple fusion of the subtalar, calcaneocuboid and talonavicular joints is required. Sometimes this is used in patients without deformity who have severe or fixed deformity or have a high BMI.
- A triple fusion is functionally less desirable than a reconstruction and therefore surveillance of symptomatic patients is very important in order to prevent disease progression to this stage.

2. Acquired Adult Flatfoot Deformity - High Value Clinical Pathway

2.1 Primary Care

- Any patient with a history of diabetes or trauma and a new onset of flatfoot deformity should be referred to a Consultant Orthopaedic Foot and Ankle surgeon for acute review.
- Patients with pre-existing or recent onset of symptomatic flatfeet should be referred to MSK podiatry for assessment and orthotic provision. If the deformity is recent onset or deteriorating this should be made a priority.
- Patients with rest or night pain and a rigid flatfoot should be referred directly to a Consultant Orthopaedic Foot and Ankle Surgeon.
- The investigation of AAFD is based on the history, clinical findings. Weight bearing radiographs +/- alignment views are used for surgical planning but non-weight bearing views performed in primary care are rarely helpful and imaging is best left until seen in secondary care.

Suggested management algorithm:

1. Acute Foot: History of diabetes or trauma, red, hot or swollen Foot

- If this is a history of diabetes complications related to it should always be considered. The Charcot foot is covered in the Pathway related to Diabetic foot disease. It presents with a red, hot swollen foot and requires urgent Consultant review.
- A new onset of flatfoot deformity following recent trauma requires urgent review in fracture clinic.

2. MINIMALLY symptomatic and FLEXIBLE flatfoot:

- If the patient can go up onto tip-toe unaided standing only on

the affected foot and the foot is flexible when assessed on the couch many patients will get significant temporary and long-term relief of symptoms from referral to MSK Podiatry and orthotic management.

- Follow up of symptomatic patients at 6-monthly intervals is recommended.

3. MARKEDLY symptomatic or RIGID flatfoot:

- If the patient is unable to go up onto tip-toe unaided and standing only on the affected foot or if the foot is not correctable when assessed on the couch:
 - Refer to a Consultant Orthopaedic Foot & Ankle Surgeon for assessment and consideration of surgery.
- If the patient is unresponsive to conservative treatment or there is significant rest or night pain and limitation of function:
 - Refer to a Consultant Orthopaedic Foot & Ankle Surgeon for assessment and consideration of surgery.
- In the presence of deteriorating foot shape :
 - Refer for an URGENT expert opinion from a Consultant Orthopaedic Foot & Ankle Surgeon.

2.2 Specialist Community and Secondary Care - Non-operative Care
Commissioned services must be integrated and include the following skills:

- MSK Podiatry
- Orthotists
- Orthopaedics Surgery
- Rheumatology
- Providers should adopt a shared decision making model, define treatment goals and take into account personal circumstances

Assessment:

- History: pain, functional impairment, medical history

- Examination: foot deformity, tibialis posterior dysfunction, pulses and sensation
- Investigation: not indicated

Management:

- Footwear assessment and provision of offloading orthotics as appropriate

Urgent referral (<2/52)

- Suspicion of Charcot disease or trauma

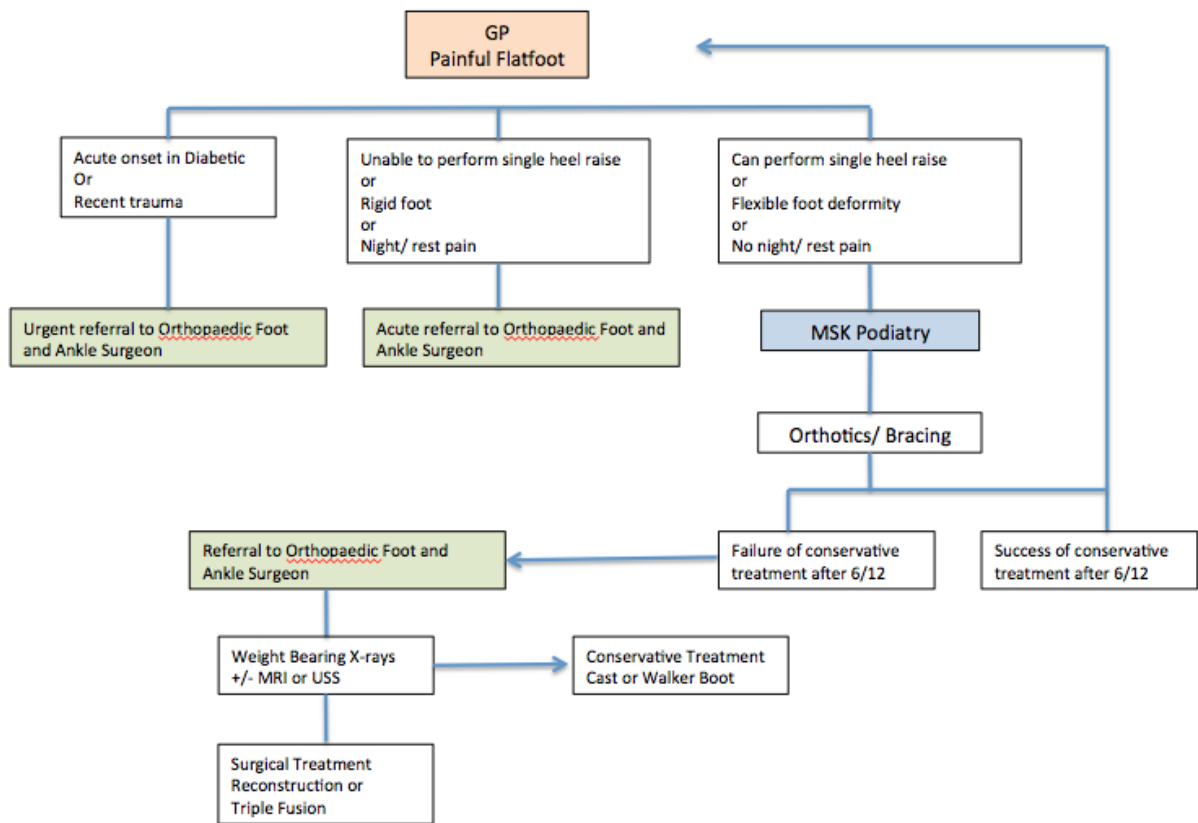
Referral to Orthopaedic Foot and Ankle Surgeon

- Diagnosis of other conditions in Appendix 1
- Rest or night pain, rigid foot, marked functional impairment
- Unresponsive to treatment for >6 months
- Deteriorating foot shape/pain

Assessment

- 1 Confirm diagnosis of AAFD- exclude other conditions listed in Appendix 1.
- 2 Assess alignment of the forefoot/midfoot/hindfoot in relation to lower limb
- 3 Assess for underlying risk factors- gastrocnemius contracture, hypermobility and muscle/ tendon imbalance.
- 4 Assess for the presence of degeneration
- 5 Consider USS to assess the Posterior Tibial tendon or MRI to assess the presence of adjacent joint arthritis

- Counsel patient fully regarding operative and non operative options
- Ensure multidisciplinary approach- service should have availability of MSK podiatrists, orthotists, and physiotherapists (+/- hydrotherapy), specialist care nurses and plaster room technicians.
- Data Collection – PROMs for all patients and/or validated clinical scores.



2.3 Specialist Community and Secondary Care - Operative Care

Assessment:

- History: pain, functional impairment, medical history
- Examination: foot deformity, tibialis posterior dysfunction, pulses and sensation
- Investigation
 - Weight-bearing x-rays
 - USS to assess the tibialis posterior tendon
 - MRI if arthritis is suspected

Management:

- Providers should adopt a shared decision making model, define treatment goals and take into account personal circumstances, all alternatives MUST be discussed
- Patient Information should be provided

Surgery:

- Should only be undertaken by an Orthopaedic Foot and Ankle Surgeon
- Is usually 24-48 hour admission unless clinical or social circumstances dictate otherwise.
- Patients will have significantly limited mobility for 6-8 weeks post surgery. Patients who are likely to have difficulty non-weight bearing post-operatively should be identified and assessed by physiotherapy and occupational therapy services. It may be necessary for patients living alone to have planned admission to a rehabilitation unit after surgery.
- Patients will require venous thromboprophylaxis for six weeks unless contra-indicated.
- A number of post-operative follow-up appointments are required and will include cast changes, standing radiographs and physiotherapy over a 6-12 month period.

Surgical Procedures:

- Surgery is simpler and more successful in the earlier stages of deformity.
- There are a number of surgical options and adjunctive procedures that may be required and the Johnson and Strom Classification (Abousayed, Tartaglione, Rosenbaum, & DiPreta, 2015) is used to guide management:

Stage I Disease

- The standard procedure is debridement, this may be supplemented with the use of an arthrodesis screw (Fernández de Retana, Alvarez, & Bacca, 2012).

Stage II Disease

- The standard procedure is a Flexor Digitorum Longus transfer, Calcaneal Osteotomy and Spring ligament Reefing.
- Adjunctive procedures include gastrocnemius recession, midfoot fusion or osteotomy and subtalar arthrodesis.

Stage III Disease

- The standard procedure is a triple arthrodesis of the subtalar, calcaneocuboid and talonavicular joints.

Stage IV Disease

- The standard procedures are a pantalar fusion or a triple fusion and ankle replacement.

Research

2.3 Research & Audit

- Patient Reported Outcome Measures - A validated clinical score (or PROM) should be captured preoperatively and one year following treatment. Acceptable scores include; Manchester-Oxford Foot & Ankle Questionnaire (MOXFQ), Foot Function Index (FFI).
- Quality of Life Scores should be captured preoperatively and one year following intervention (e.g. EuroQol (EQ5D) or Short Form-SF36)

2.4 Linked Metrics

2.5 Patient/ Public/ Clinician Information

- Patient information - Patients must be counselled preoperatively regarding the benefits and risks of all surgical options and also the merits of non-operative management.
- GP guidance - easily accessible information on the risks and benefits of surgical intervention needs to be made available.

3. Adult Acquired Flatfoot – The Evidence base

Recognised non-operative treatments for AAFD include:

Activity modification, ankle bracing and AFO splints, physiotherapy (R. G. Alvarez, Marini, Schmitt, & Saltzman, 2006), orthotics (Chao, Wapner, Lee, Adams, & Hecht, 1996;

Houck, Neville, Tome, & Flemister, 2015), footwear adjustments, use and appropriate analgesia (Nielsen et al., 2011). Although the evidence base for these modalities is not comprehensive, the costs are low and many patients will get significant temporary and long-term relief of symptoms from a comprehensive package of individually tailored conservative care.

Surgical Procedures:

1 Reconstruction

Classic reconstructive surgery involves transfer of the Flexor Hallucis Longus tendon to replace the failed tibialis posterior tendon, a repair of the Spring ligament and a calcaneal osteotomy to support these soft-tissue reconstructions. Other procedures such as a gastrocnemius release (Silva, Tan, Chong, Su, & Singh, 2015), arthrodesis screw (Zhu & Xu, 2015), or midfoot fusion may be used as adjunctive procedures.

Recovery takes 6-10 months and the patient will be non-weight bearing for at least 6 weeks. Maximal benefit will take more than 1 year.

This is a major operation however the results are favourable with good levels of function post-operatively and the results are better than triple fusion (Taylor & Sammarco, 2012). It is therefore imperative to prevent patients from deteriorating into stage III and IV disease.

2 Triple Fusion

This procedure involves fusion of three major hind foot joints rather than reconstructing the failed tendon. It is used in the rigid or arthritic flatfoot.

Recovery takes 6-10 months and requires the patient to be non-weight-bearing for at least six weeks.

The complication rate is higher than reconstruction, notable the risk of non-union requiring further surgery. The functional outcomes are also not as good as reconstruction (Catanzariti, Dix,

Richardson, & Mendicino, 2014). Maximal recovery will take more two years.

Appendix 1

Adult Acquired Flatfoot Deformity

1 Physiological Flatfeet that decompensate

2 Posterior Tibial Tendon Dysfunction

Other causes to be considered

3 Diabetes

a Charcot disease

4 Post-traumatic

a Fractures –especially to the midfoot

b Ligament injury- especially Spring ligament and Lisfranc

5 Degenerative

a Arthritis

6 Inflammatory

a Rheumatoid Arthritis

7 Congenital

a Accessory Navicular

b Tarsal coalition

c Arthrogyrosis

d Congenital vertical talus

e Corrected congenital talipes equinovarus

8 Collagen Disorders

a Hypermobility syndrome

b Ehlers Danlos

9 Neuromuscular

a Cerebral Palsy

Appendix 2 Johnson and Strom Staging and Management

	Stage I	Stage II	Stage III	Stage IV
Tendon condition	tenosynovitis	elongation	elongation	
Hindfoot	mobile, normal	mobile, valgus	fixed (lack of passive inversion)	Valgus tilt of talus in ankle
Pain	medial, focal	medial, along tendon	medial + sinus tarsi/lat ankle	
Single heel rise test	Normal/ mild weakness	Unable to do	absent	absent
"Too many toes" sign	normal	positive	positive	positive
Pathology	tenosynovitis	degeneration	degeneration	Ankle OA
Treatment	Conservative-orthosis/ debride	If orthosis fails - Calc osteotomy and FDL=>tib post transfer + plicate spring ligament	subtalar or triple arthrodesis depending on which joints involved	pantalar fusion or triple and ankle replacement

References

- Abousayed, M. M., Tartaglione, J. P., Rosenbaum, A. J., & DiPreta, J. A. (2015). Classifications in Brief: Johnson and Strom Classification of Adult-acquired Flatfoot Deformity. *Clinical Orthopaedics and Related Research*, 1–6.
doi:10.1007/s11999-015-4581-6
- Alvarez, R. G., Marini, A., Schmitt, C., & Saltzman, C. L. (2006). Stage I and II posterior tibial tendon dysfunction treated by a structured nonoperative management protocol: an orthosis and exercise program. *Foot & Ankle International*, 27(1), 2–8.
- Catanzariti, A. R., Dix, B. T., Richardson, P. E., & Mendicino, R. W. (2014). Triple arthrodesis for adult acquired flatfoot. *Clinics in Podiatric Medicine and Surgery*, 31(3), 415–433.
doi:10.1016/j.cpm.2014.03.004
- Chao, W., Wapner, K. L., Lee, T. H., Adams, J., & Hecht, P. J. (1996). Nonoperative management of posterior tibial tendon dysfunction. *Foot & Ankle International*, 17(12), 736–741.
- Fernández de Retana, P., Alvarez, F., & Bacca, G. (2012). Is there a role for subtalar arthroereisis in the management of adult acquired flatfoot? *Foot and Ankle Clinics*, 17(2), 271–281.
doi:10.1016/j.fcl.2012.03.006
- Houck, J., Neville, C., Tome, J., & Flemister, A. (2015). Randomized Controlled Trial Comparing Orthosis Augmented by Either Stretching or Stretching and Strengthening for Stage II Tibialis Posterior Tendon Dysfunction. *Foot & Ankle International*. /

- American Orthopaedic Foot and Ankle Society [and] Swiss Foot and Ankle Society, 36(9), 1006–1016.
doi:10.1177/1071100715579906
- Kohls-Gatzoulis, J., Woods, B., Angel, J. C., & Singh, D. (2009). The prevalence of symptomatic posterior tibialis tendon dysfunction in women over the age of 40 in England. *Foot and Ankle Surgery : Official Journal of the European Society of Foot and Ankle Surgeons*, 15(2), 75–81.
doi:10.1016/j.fas.2008.08.003
- Nielsen, M. D., Dodson, E. E., Shadrick, D. L., Catanzariti, A. R., Mendicino, R. W., & Malay, D. S. (2011). Nonoperative care for the treatment of adult-acquired flatfoot deformity. *The Journal of Foot and Ankle Surgery : Official Publication of the American College of Foot and Ankle Surgeons*, 50(3), 311–314. doi:10.1053/j.jfas.2011.02.002
- Silva, M. G. A. N., Tan, S. H. S., Chong, H. C., Su, H. C. D., & Singh, I. R. (2015). Results of operative correction of grade IIB tibialis posterior tendon dysfunction. *Foot & Ankle International. / American Orthopaedic Foot and Ankle Society [and] Swiss Foot and Ankle Society*, 36(2), 165–171.
doi:10.1177/1071100714556758
- Taylor, R., & Sammarco, V. J. (2012). Minimizing the role of fusion in the rigid flatfoot. *Foot and Ankle Clinics*, 17(2), 337–349.
doi:10.1016/j.fcl.2012.03.010
- Zhu, Y., & Xu, X.-Y. (2015). Treatment of Stage II Adult Acquired Flatfoot Deformity With Subtalar Arthroereises. *Foot & Ankle Specialist*, 8(3), 194–202. doi:10.1177/1938640014548320